




EFTBA Veterinary Newsletter 15



Fetal gender determination in the mare

Welcome to EFTBA's veterinary newsletter

Dear European breeders,

You are about to read the EFTBA Veterinary Newsletter dedicated this time to gender determination in the pregnant mare amongst other very interesting topics.

Dr Hanspeter Meier is bringing, once again, a veterinary subject that has huge economic consequences for the market values of our horses. I would advise each European breeder to take the time to read carefully this article and so

that we all raise our knowledge in advanced veterinary sciences and technologies.

With kind regards

Loïc Malivet

Loïc Malivet

Chairman, EFTBA

Editorial

According to our homepage, betting and gambling, VAT, employment legislation, animal health and welfare including import and export controls are the main areas of work for the EFTBA. Of course, this list finds my understanding and consent, and I can also assure whole-heartedly that the work of a breeders' association on the national level also embraces economic and political issues for more than 90% of ones duties. But nevertheless, our principal aim is breeding and the spring reminds us happily of the fascination of foaling and

covering mares.

Therefore some news of veterinary progress in this field may hopefully be welcome as well.

Moreover, informations for a meeting for breeders, trainers and owners in Baden-Baden (GER) at the end of August on actual subjects of "business and ethics of racing and the role of the veterinarian" are attached as well.

Dr Hanspeter Meier

EFTBA veterinary advisor & Newsletter editor

April 2015

. Ultrasonic imaging is a most helpful diagnostic technique in stud-medicine generally.

. One of its great advantages is the possibility to examine the equine fetus in many respects

. Color Doppler Sonography allows examining the fetal sex in mid- and advanced-gestation reliably

"Many thanks to Mrs. Eva-Maria Bucher-Haefner, Moyglare Stud Farm, for her valued sponsorship of this newsletter."



Profound Beauty (Danehill) owned and bred by Moyglare Stud.

Introduction

For the care and management of the broodmare, the introduction of ultrasonic imaging at about 30 years ago was a significant milestone both for breeders and veterinarians. It allows the visual presentation and the documentation of just about any structure and event in the reproductive cycle and pregnancy, of embryo-uterine interactions as well and of important features of the conceptus as e.g. its sex. The latter did find interest already quite some time ago and first reports on determining the gender of the equine fetus date back to the late eighties and the nineties of the last century (e.g. Curran and Ginther 1989, Curran and Ginther 1993, Holder 1999). Due to the poorer technical possibilities of that time, these first examinations allowed investigations only in a short time at the beginning of the pregnancy.

Progress was made by the ladies Renaudin et al. (1999) and Bucca (2005) with studies during mid- and advanced gestation and in our days now, the method of Doppler ultrasonography created even better possibilities for examining the gender of a fetus (Resende et al. 2014, Tönissen et al. 2015).

Some earlier research on fetal gender determination in the mare

Renaudin et al. (1999): **Transabdominal ultrasonographic determination of fetal gender in the horse during mid-gestation.**

These scientists in California studied the gender determination of the equine fetus by using transabdominal ultrasonography in 20 mares. One group of 10 research mares was scanned repeatedly every 2 weeks from 100 days gestation to parturition, while the second group of 10 client mares was subjected to echography once during mid-gestation.

In **males**, the penis and/or prepuce was observed on 71 occasions from 102 days to 258 days gestation. Fetal testes were oval in shape in frontal view and had an homogeneous ultrasonographic appearance.

Females were diagnosed on 23 occasions from 118 days to 227 days gestation based on the presence of the mammary glands and teats. Fetal ovaries appeared homogeneous with a characteristic circular echo from 100 days to 134 days gestation.

Gender identifications (n = 98) based on the presence of the penis and/or prepuce in males and mammary glands and teats or fetal gonads in females were all correct, in agreement with the sex

of the foals at birth. The optimal **window of time** was defined in both sexes at **100 to 220 days** gestation.

Thereafter, it was increasingly difficult to identify the anatomical structures cited above. Fetal sex was mainly determined using the transabdominal approach (87/98). However, the transrectal examination was useful in cases in which fetuses were either in posterior presentation or located very high in the mares abdomen.

Bucca (2005): **Equine fetal gender determination from mid- to advanced-gestation by ultrasound.**

Fundamentals for to-days possibilities of examining the fetal sex in mid- and advanced-gestation by Doppler-Ultrasound were also established by Bucca (2005) from the Irish Equine Centre.

According to her, early equine fetal sexing techniques, performed between approximately days 58 and 70, didn't find great publicity, due to the pretty narrow diagnostic window. She therefore developed a method for determining the equine fetal gender by conventional (B-mode) ultrasound between days 120 and 210. With the combination of transrectal and transabdominal ultrasound examinations, she was able to visualise fully developed fetal primary sex organs up to 8 months of gestation.

Color Doppler Sonography for gender diagnosis

Further and recent progress was made in 2014 and 2015 with the method of color Doppler Ultrasonography which allows the detection of blood circulation and flux of liquid in the fetal gonads (testes and ovaries) and thanks to this an even better diagnosis.

Resende et al. (2014): **Determination of equine fetal sex by Doppler ultrasonography of the gonads.**

In this short communication, the Brazilian authors remind us of the fact, that during early gestation (58-70 days of pregnancy), fetal sex determination in horses and cattle is based on the identification and location of the genital tubercle, which is initially located on the mid-line between the hindlimbs. It is the precursor to the penis in a male and the clitoris in a female. It is sonographically visible as a hyperechogenic, bilobulated structure about two millimeters in diameter. Around Day 55 of gestation, the tubercle migrates a short distance in the caudal direction (ventral to the tail base) in females, becoming the clitoris, and in males, the genital tubercle migrates a greater distance in the cranial direction, to immediately behind the umbilical cord, be-

coming the penis. However, this technique has 2 limitations: it requires a very experienced examiner and it allows fetal sex determination only during a short window of time, with the optimal time being between 59 and 68 days. Moreover, in horses, the conceptus contains a large amount of allantoic fluid and the fetus is highly mobile with a long umbilical cord, which hampers the positioning of the transducer on the fetus and the visualisation of its structures.

The **detection of fetal sex at 90–150 days of pregnancy** is based on **visualisation of the fetal gonads**. Doppler transrectal ultrasonography is a practical, efficient, noninvasive and real-time method for assessing blood flow in the reproductive tract. The aim of this study was to determine the efficacy of colour Doppler ultrasonography in the detection of equine fetal sex.

Resende et al. (2014) investigated 86 pregnant mares of different breeds (Quarter Horses, Mangalarga Marchador and crossbred mares) aged 5 - 7 years and at **90 -180 days** of pregnancy.

Their findings were that fetuses that had gonads with a **homogeneous texture** (testicular parenchyma) **and a thin central longitudinal echogenic line** (mediastinum) were considered to be **male**.

Females were identified by the presence of gonads with **a central circular echogenic structure** (cortical border) **surrounded by a hypoechogenic external halo** (medulla) (Fig. 1a) and a **ring of vascularisation** between the cortical and medullary layers of the ovary with colour Doppler ultrasonography (Fig. 1b). In **male fetuses**, the Doppler method was used to identify the **vascularisation of the pampiniform plexus and testicular vein**.

At birth, the sex of the foals was compared with a diagnosis made between 90 and 180 days of pregnancy using B-mode and colour Doppler ultrasonography.

Results: Using **B-mode ultrasonography**, it was possible to determine the sex of **75% of the males**, while determination of sex based on differences between the medullary and cortical layers of the ovary allowed **91.1% of females** to be correctly identified.

Using **Doppler ultrasonography**, **100% of males were successfully identified**, while characteristic vascularisation of the **female gonad could be detected in 98% of the evaluated female fetuses**.

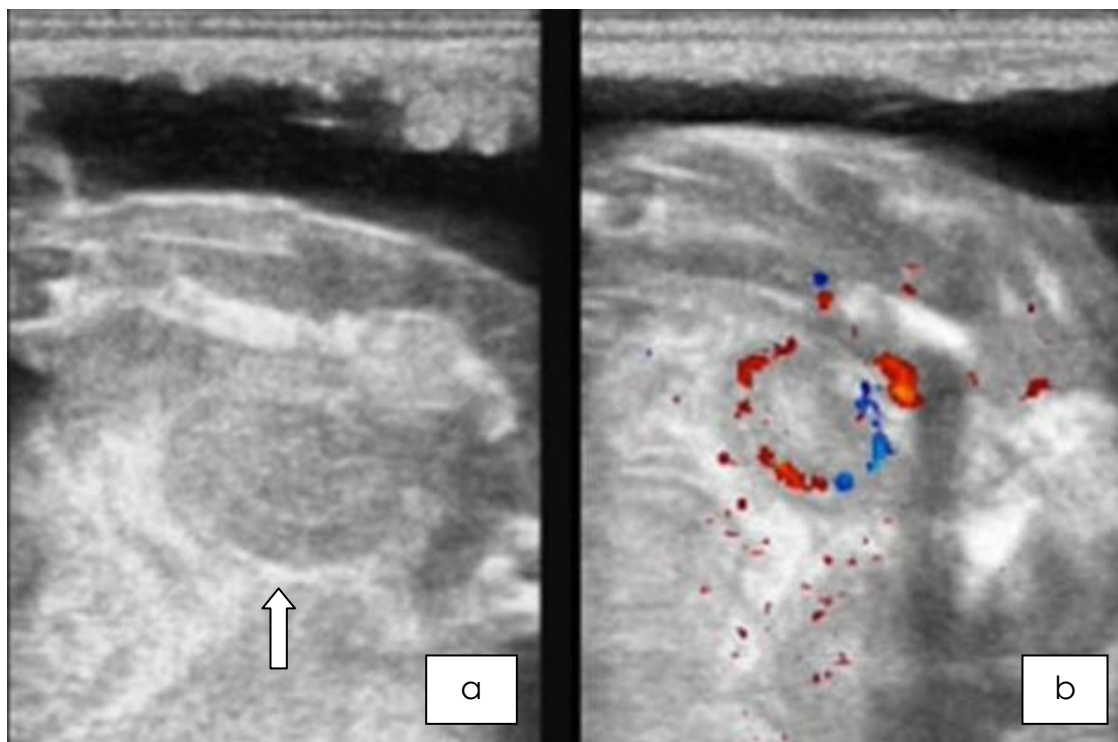


Fig. 1: a) Female gonad (ovary, arrow) visualised by conventional B-mode ultrasonography and b) border vascularisation between the cortical and medullary layers of the ovary as depicted by colour Doppler ultrasonography (Resende et al. 2014).

Tönissen et al. (2015): **To perform fetal gender determination in the mare by ultrasound during early and advanced gestation.**

The German scientists reviewed the current knowledge on equine fetal sexing and described the principles and methods of scanning very comprehensively. They agree with the already mentioned possibilities and limitations of early gender diagnosis (days 59-68) and concentrate on examinations in more advanced gestation. In their opinion, **gender determination** can also be conducted beginning **on day 90 up to day 260**. The examination of the mares after the breeding season, throughout the year, is therefore possible. This is a great advantage both for the breeder and usually for the examiner as well, because of the lower workload after the season. Moreover, the window of time is wider and gender-specific differences increase. Several parameters of the fetal well-being can also be gathered, such as movement and heart rate, aortic diameter and growth of the fetus. Fetoplacental well-being can be evaluated too, important parameters for that purpose are combined thickness of uterus and placenta (CTUP), the echogenicity of fetal fluid and the presence of echogenic free floating particles.

Late fetal sex determination is based on the identification of different distinctive features, in the male fetus penis, prepuce, scrotum and gonads, in the female fetus mammary glands including nipples, vulva, clitoris and the gonads can be visualized. Access can be gained to the regions of interest by transrectal (90-150 days) or transabdominal ultrasonography, or by a combination of both techniques, depending on fetal presentation and movement.

They mention that the hindquarters of the fetus are reachable by transrectal examination from 90 until 140 days only. During this stage of gestation sex determination will be based on the external genitalia and the gonads. **After 150 days**, in most cases the fetus is found in anterior position wherefore fetal hindquarters appear in the mid abdomen and they move further cranial due to growth of the fetus. **After 8 months** of pregnancy, they are found in the cranial third of the abdomen near the xyphoid. For these stages of gestation, the transabdominal approach must be chosen.

Results: The gonads are equally shaped and located in both sexes, in the **male fetus** with a homogeneous echogenicity and a typical hyperechogenic line along the longitudinal axis in the middle of the gonad with an intense Doppler signal (see Fig. 2a & b). In the **female gonads**, the echogenicity is bizoned, because of the different structure of cortex

and medulla. These features can be visualized even better by using color Doppler ultrasonography (as in Fig. 1).

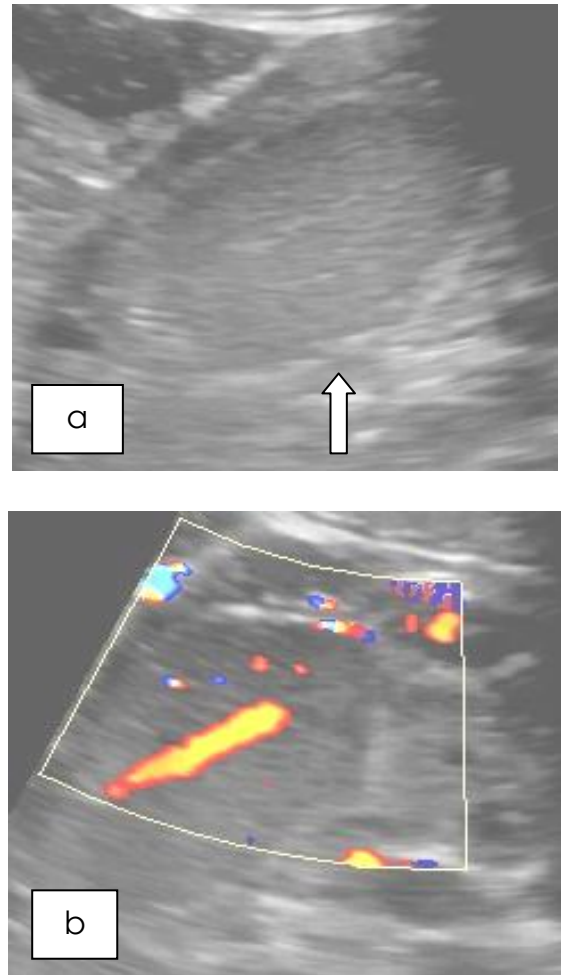


Fig. 2: a) Fetal male gonad (testicle, arrow) at day 219 visualised by B-mode and b) fetal male gonad with an intense Doppler signal along the longitudinal axis representing liquid flux in the mediastinum testis and signals on the lateral contour representing blood flow (Tönissen et al. 2015)

Reasons for performing these studies ...

According to some of the cited authors, knowledge of a fetus' sex enables the horse owner or breeder to manage several different aspects of his or her horse business better. For example, the value of a foal frequently is influenced by its gender, depending on its sire or dam. Therefore, one may be more accurate in assessing the value of a pregnant mare by knowing the sex of her fetus. Appraisals, selling decisions, reserves at auction, insurance coverage, mating lists, prepurchase limits, collateral limits, and

foaling locations all are influenced by this information (Holder 1999).

Renaudin and co-workers (1999) mention that mare owners have an increasing interest in fetal gender determination. Firstly, nonprofessional breeders are usually curious to know. They may prefer females because they are easier to handle than males and can continue to carry on their breeding programmes. Secondly, professional breeders are interested in this information in order to predict their budget, because the sex of the fetus can directly influence a sale. Some stallions are known to have a greater proportion of quality female or male offspring, and their stud fees are higher for one sex or the other.

The Brazilian authors consider the diagnosis of equine fetal sex also as a useful service for breeders because knowing the sex of a fetus in advance allows the implementation of different commercial strategies, such as increasing the stipulated value of a pregnant mare or insisting on a particular crossing at the next mating (Resende et al. 2014).

Tönissen et al. (2015) justify their investigation with economic aspects as well and are of the opinion that due to the difficult economical situation in horse breeding, commercial interests do become more important. The value of a pregnant mare can be set differently if the gender of the fetus is known and decisions about the future of broodmares can be made based on the sex of the offspring. Knowing the possibility to identify its gender in advance, breeders are interested for different reasons and may use this technique for managing their stock.

... and some reflections from down-under
(breedingracing.com June 2013)

Australian Breeders Shun Foetal Sex Determination

Despite being widely used by breeders in the US, Australian breeders have largely shunned in-utero sex testing for foals developed more than 10 years ago writes Renée Geelen.

Magic Millions managing director Vin Cox reveals that costs associated with foetal gender testing in thoroughbreds have contributed to its slow uptake locally, noting: "The technology has gained a strong foothold in America, while remaining fairly unused here and perhaps the main reason for that is that breeders are unwilling to spend money on the additional test required when the answer is not going to change the outcome. Having said that, when selling a broodmare, breeders may embrace this technology in the future to help them make key decisions about when to sell. In the US, breeders like to

know what they are expecting and use the technology to plan their bloodstock interests with more certainty."

Such has been its acceptance in the US, mares are sold with the disclaimer "Believed to be carrying a colt" (or filly).

In terms of the testing potentially gaining more relevance in Australia, Cox suggests changing market forces and trends might become a factor: "The changing breadth of gap between the value of colts and fillies as yearlings may also affect the decision as to whether or not to do this test."

This has added relevance given that Australia is on the doorstep to the lucrative Asian racing market that primarily buys colts.

Inglis director Jonathan D'Arcy says, "Doing gender testing on in-foal broodmares is still relatively rare in Australia, and it is currently left up to vendors to notify potential buyers of any test results they wish to pass on prior to the mare being offered in the ring. With regards to the American situation, Inglis have always been concerned about the legal ramifications if a statement was made by the auctioneer stating that a mare was carrying a foal of a certain gender, and then 5 months later the mare foaled the opposite of what was announced."

Despite the improvements in testing over the past decade, D'Arcy states: "While I am sure that advancements in veterinary science have seen the test become almost foolproof, we are yet to hear from too many of our clients that they want this information used at sale time. What I would say is that breeders who are testing for the gender of their unborn foals have a moral obligation to share this information with interested buyers at a sale. We are, as always, willing to discuss any change with breeders and our fellow sales companies if clients were to ask for a change in the Conditions of Sale to cover this issue."

Renowned Australian reproduction veterinarian and lecturer at Charles Sturt University, Dr Allan Gunn, spoke to Breeding&Racing about the technology and its use in Australia. Equine foetal sex determination was initially developed by American vet Dr Richard Holder in the late 1990s, and is done between 55 and 150 days of pregnancy. Although Holder claims in his scientific papers on the subject that the correct gender can be determined correctly 95% of the time, Gunn believes that the actual outcome is more dependent on the experience of the ultrasonographer, with accuracy ranging from little more than guesswork up to Holder's estimate.

Gunn says that the technology is not utilised often in Australia, largely because of the timing of the test.

The gender of a foetus can't be determined until after 55 days, after the typical set of scans performed on a broodmare are complete. And therefore, the determination of gender requires an additional scan and thus an additional expense that the majority of broodmare owners don't see as necessary when it isn't going to alter the foal that arrives.

According to the CIA Fact Book, the human global sex ratio is 101 males to 100 females; but this varies with a range of factors. There are over 1,000 publi-

shed studies on human gender ratios and different factors that impact on them. These include parental age, birth order, social drivers (eg the one child policy in China and the bias towards male progeny in India), race, economic status, chemical pollutants, and even climate change.

In racehorses, the ratios are closer to neutral with The Australian Stud Book records for those seasons below showing the numbers of colts and fillies born in Australia. There are some slight seasonal variations, but it works out to almost a 1:1 ratio with 99.95 colts for every 100 fillies born.

Year of Foaling	Colts	Fillies	Colts per 100 Fillies	% Colts	% Fillies
2010	8,175	8,194	99.77	49.9%	50.1%
2011	8,062	7,897	102.09	50.5%	49.5%
2012	6,940	7,097	97.79	49.4%	50.6%
Total	23,177	23,188	99.95	50.0%	50.0%

To discover how these figures are translating into the sales ring, Arion Pedigrees put together a list of all the broodmares sold in Australia in 2010, 2011 and 2012 along with the gender of the foals they had that season. The sales results were compiled into tables:

Live Foals From Catalogued Mares

Broodmares that had a live foal after being catalogued	Colt	Filly	Total	Colts per 100 Fillies	% Colts	% Fillies
Sold	1,916	1,894	3,919	101.16	50%	50%
Passed	620	600	1,261	103.33	51%	49%
Withdrawn	426	393	850	108.40	52%	48%
Total	2,962	2,887	6,030	102.60	51%	49%

Broodmares that had a live foal after being sold

Broodmares that had a live foal after being sold	Colt	Filly	Total	Colts per 100 Fillies	% Colts	% Fillies
\$50k Plus	291	299	599	97.32	49%	51%
\$20k-49k	334	309	659	108.09	52%	48%
\$5k-19k	537	528	1,098	101.70	50%	50%
Under \$5k	754	758	1,563	99.47	50%	50%
Total Sold	1,916	1,894	3,919	101.16	50%	50%

While it might look like there is a slight sway towards colts or fillies in different price brackets, the reality is that the numbers sold are relatively small and are within statistical range of a 50/50 result. From a simplistic point of view, readers will notice that the only samples that had a greater difference than 49/51 were those with less than 1,000 lots, so basically from a statistical point of view they are neutral as well.

On the issue of gender scanning prior to selling a mare, Dr Allan Gunn told *Breeding&Racing* that these results line up with what he would expect given that, even when owners bother to do a gender scan on their mare, they are equally likely to keep or sell a filly depending on what they are

looking for. For instance, a breeder might keep a mare carrying a filly in order to continue breeding from the family, while another breeder may sell a mare carrying a filly because they perceive the cost to bring that filly foal to the sales to be too high relative to a colt from the same mare.

In conclusion, foetal sex determination appears to be largely irrelevant to the broodmare sales in Australia. Most breeders, it seems, would rather punt on a 50/50 chance than spend the money to find out, especially when the test is not 100 percent accurate, and sales figure differences don't yet appear to warrant testing (Geelen 2013).

References

Bucca S. (2005): Equine fetal gender determination from mid- to advanced-gestation by ultrasound. *Theriogenology*, August 64(3), 568-571

Curran S. and Ginther O.J. (1989) Ultrasonic diagnosis of equine fetal sex by location of the genital tubercle. *J. equine vet. Sci.* 9, 77-83.

Curran S. and Ginther O.J. (1993) Ultrasonic fetal gender diagnoses during months 5 to 11 in mares. *Theriogenology* 40, 1127-1135.

Geelen R. (2013): Australian Breeders Shun Foetal Sex Determination. *Breedingracing.com*, 6th June.

Holder R.D. (1999): Equine Fetal Sex Determination. *TheHorse.com*, April 1.

Renaudin C.D., Gillis C.L. and Tarantal A.F. (1999): Transabdominal ultrasonographic determination of fetal gender in the horse during mid-gestation. *Eq. Vet. J.* 31 (6) 483-487

Resende H.L., Carmo M.T., Ramires Neto C. and Alvarenga M.A: (2014): Determination of equine fetal sex by Doppler ultrasonography of the gonads. *Eq. Vet. J.* 46 (2014) 756-758, DOI: 10.1111/evj.12213

Tönissen A. , Martinsson G., Otzen H., Schürmann K., Schütze S., Ertmer F., Kassens A., Sielhorst J., Brehm R. and Sieme H. (2015): To perform fetal gender determination in the mare by ultrasound during early and advanced gestation. *Pferdeheilkunde* 31 (2) March/April, 153-158

Business and ethics of racing and the role of the veterinarian

Meeting for trainers, breeders and owners

Friday 28th of August, Palais Biron in Baden-Baden (Lichtentalerstrasse)

Program

- 10.00 Welcome and introduction (S. Eversfield)
 - 10.15 The life of a racehorse – 150 years ago and to-day (H.P.Meier)
 - 10.30 How to finance racing in future (B. Forndran)
 - 10.45 Using databases to predict risk (T. Parkin)
 - 11.00 Sustainability as a framework for Thoroughbred protection – why and what does it entail? (I. M. Bergmann)
 - 11.15 Joint and tendon stress in young Thoroughbreds (R. van Weeren)
 - 12.00 The application of commercial genetic tests for racing performance in the global Thoroughbred industry (E. Hill)
 - 12.15 Long distance elite horse transport and its effects and consequences (D. Leadon)
 - 12.30 Biosecurity protocols for studfarms (H. Sieme)
 - 12.45 Equine gastric ulcers : what's up doc? (C. Scicluna)
 - 13.00 Managing the risks of prohibited substance from feeds and supplements (M. Dunnett)
 - 13.15 A second chance for old friends - the care and management of retired racehorses (H.P. Meier)
- Lunch and farewell

Information and registration:

Hippiatrika publishing, P.B. 100085, 76481 Baden-Baden-Germany

Phone: 0049 (0)176 23 41 14 22

Registration online or by fax

www.racing.care

Email: reg@racing.care / Fax: 0049 (0)561 97 01 07 02

Bank: GLS Bank

IBAN: DE31 4306 0967 7025 2078 00

BIC: GENODEM1GLS

Fees:

Early booking (till June 30)	160 €
Normal (July 1 – August 20)	180 €
Late booking (after August 20)	200 €
Congress Dinner Friday	60 €
Casino Dinner Saturday	60 €
Champions Club Saturday (Racing)	150 €

The social events Congress Dinner on Friday evening and Casino Dinner on Saturday evening must be booked separately. The meeting fees must be payed in advance after reception of the bill of charges. Please note clearly the participant's name and bill number. Charging without V.A.T. is not possible.

**European Federation of
Thoroughbred Breeders
Associations**

**257 Avenue le Jour se
Lève**

92655 Boulogne CEDEX

France

Phone:

+33 4 71 58 49 17

Fax:

+33 4 71 58 41 15

E-Mail:

info@eftba.eu

Web Site:

www.eftba.eu